

## Thoracic Gunshot Wound: A Report of 3 Cases and Review of Management

Tanmoy Ganguly<sup>1</sup>,  
Sandeep Kumar Kar<sup>1</sup>,  
Chaitali Sen<sup>1</sup>,  
Chiranjib Bhattacharya<sup>2</sup>,  
Manasij Mitra<sup>3</sup>,

### Abstract

Thoracic gunshot injury may have variable presentation and the treatment plan differs. The risk of injury to heart, major blood vessels and the lungs should be evaluated in every patient with rapid clinical examination and basic monitoring and surgery should be considered as early as possible whenever indicated. The authors present three cases of thoracic gunshot injury with three different presentations, one with vascular injury, one with parenchymal injury and one case with fortunately no life threatening internal injury. The first case, a 52 year male patient presented with thoracic gunshot with hemothorax and the bullet trajectory passed very near to the vital structures without injuring them. The second case presented with 2 hours history of thoracic gunshot wound with severe hemodynamic instability. Surgical exploration revealed an arterial bleeding from within the left lung. The third case presented with post gunshot open pneumothorax. All three cases managed successfully with resuscitation and thoracotomy. Preoperative on table fluoroscopy was used for localisation of bullet.

**Keywords:** Thoracic trauma, Gunshot injury, Traumatic pneumothorax, Emergency thoracotomy, Fluoroscopy.

- 1 Department of Cardiac Anesthesiology, Institute of Postgraduate Medical Education and Research, Kolkata, India
- 2 Department of Anesthesiology, Institute of Postgraduate Medical Education and Research, Kolkata, India
- 3 Krisanganj Medical College, Institute of Postgraduate Medical Education and Research, Kolkata, India

**Corresponding author:** Sandeep Kumar Kar, Assistant Professor

✉ sndpkar@yahoo.co.in

### Introduction

Penetrating thoracic injuries have always been a nightmare to the thoracic trauma team. Patients may come with a variety of presentation and the management differs from case to case. Morbidity caused by stabbing injuries to the heart is 20-30%, while piercing wounds cause 30-60% of deaths [1]. Fatality after cardiac gunshot injury is around 80% [2-4]. Campbell et al. [5] found 94% patients with penetrating thoracic injury dies before reaching the hospital. Immediate management of these patients are very crucial and proper decision regarding surgical removal of retained bullet is of utmost importance for survival of these patients. Here we describe successful management of three patients with thoracic gunshot injury: one with vascular injury, one with airway injury and one patient with no immediate complication.

### Case Report 1

A 52 years old male patient was referred with a 3 hours history of firearm injury over left side of chest. Patient was having pain and a trickling of blood from the wound along with cough and haemoptysis. There was no history of severe respiratory distress, abnormal sound during respiration or black out. On examination,

patient was conscious, alert, oriented and cooperative. Hemodynamic was stable and no signs neurological deficit found. On auscultation, there was diminished breath sound in left side; heart sounds were clearly audible without any murmur. A 1 cm × 1 cm firearm entry wound was found in anterior left chest 4.5 cm above the nipple and just lateral to mid clavicular line with surrounding burning stain and blood trickling from the centre of the wound. No exit wound found. An intercostal chest drain was put immediately in the left side of chest and 600 ml blood came out. Patient was posted for surgical removal of the bullet and in operating room exact position was delineated with the help of fluoroscopy. Patient received antifibrinolytic (Tranexamic acid 1g) to control bleeding. Rapid sequence induction was done and a 37F double lumen endobronchial tube (DLT) was introduced. A left posterolateral thoracotomy was done and a (3 cm × 0.5 mm) bullet was found in the paravertebral gutter at the level of 10th thoracic vertebra just lateral to the aorta. The bullet was embedded in the 10th intercostal space and was removed. No active bleeding was found. Some small lacerations near hilum were repaired. There were no signs of injury to any great vessels, bronchus or the spine. An epidural catheter was placed for postoperative analgesia. Postoperatively patient was treated with antibiotics, respiratory physiotherapy, and nebulisations.

Postoperative period was uneventful. Mild hemoptysis and cough persisted for 2 days. In this case the bullet trajectory passed very near the vital structures like the heart, aorta and thoracic spine without causing any damage (**Figures 1-3**).

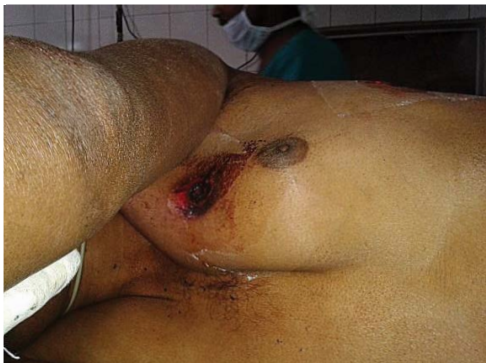## Case Report 2

A 29 years old male patient was referred with a history of firearm injury over right side of chest 2 hours back. On admission, patient was restless and complaining of cough with hemoptysis, pain and trickling of blood from the wound. On admission pulse rate was 132, blood pressure was 84/46, room air SpO2 95%, respiratory rate 26/min. On auscultation, there was diminished breath sound in left side; heart sounds were clearly audible without any murmur. A small circular wound with charred margin was found at 4th intercostals space just right to the sternal border. No exit wound found. A chest drain was introduced and immediately 700 ml bloody fluid drained. Tranexamic acid 1 g was given to control bleeding. Patient was resuscitated with ringer's lactate but hemodynamics did not improve much. Further 250 ml blood drained in next half hour. Emergency thoracotomy and ligation of bleeding vessel was planned. In the operation theatre preoperatively position of the bullet was assessed by fluoroscopy. Rapid sequence induction was done. Chest was opened via a

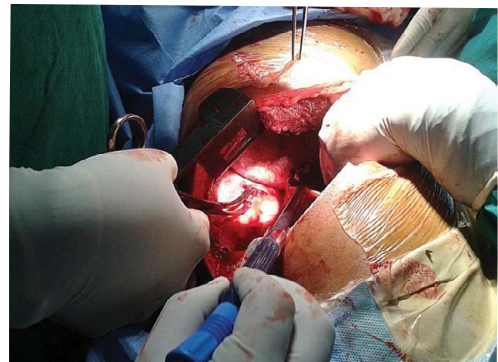
posterolateral thoracotomy. Bullet was found overlying the lung parenchyma posterolaterally. On removal of bullet a bleeder artery was found in lung parenchyma. It was ligated and hemostasis secured with cauterisation. Collapsed lung expanded well with recruitment manoeuvre and breaches in lung parenchyma were identified with high tidal ventilation with bag and repaired. Volume support was given with ringer's lactate and hydroxyethyl starch initially and packed cell transfusion was done when available. An epidural catheter was introduced after the surgery was over for postoperative analgesia (**Figures 4 and 5**).

## Case Report 3

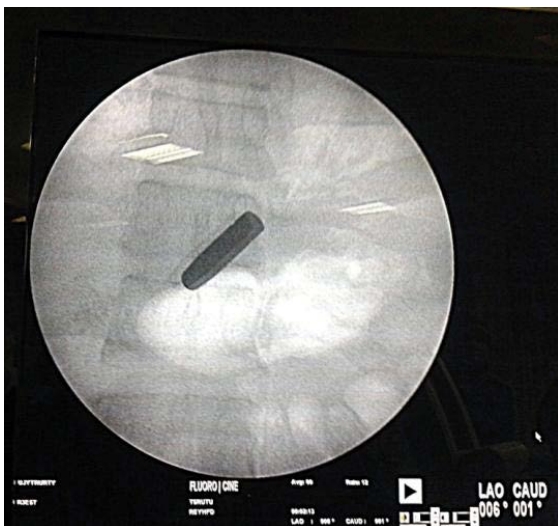A 15 year old male patient presented with a history of gunshot injury over right chest 1 hour back. Patient complained of pain, cough, breathlessness and hemoptysis. After admission pulse rate was 126/min, blood pressure 106/62, respiratory rate was 42/min, room air SpO2 was 88%. Immediate chest tube drainage was 300 ml without significant continuous bleed. There was continuous air leak through chest tube during respiration. Open pneumothorax and bronchopleural fistula was suspected and patient was posted for thoracotomy and repair. Bullet was



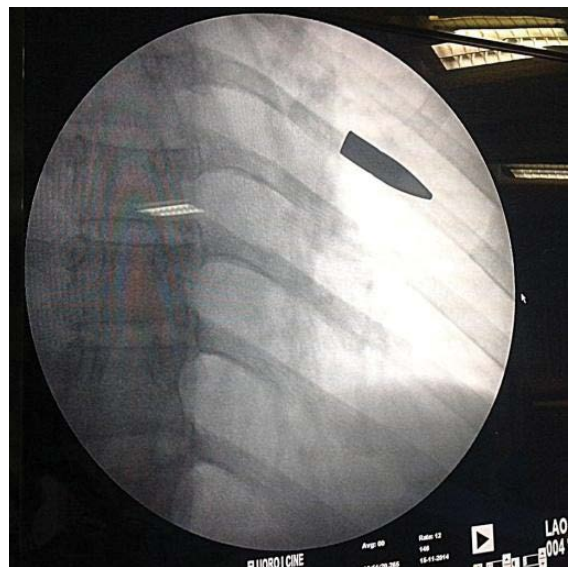
**Figure 1** Entry wound.



**Figure 3** Removal of bullet.



**Figure 2** Fluoroscopic localisation of bullet.



**Figure 4** Fluoroscopic localisation of the bullet.



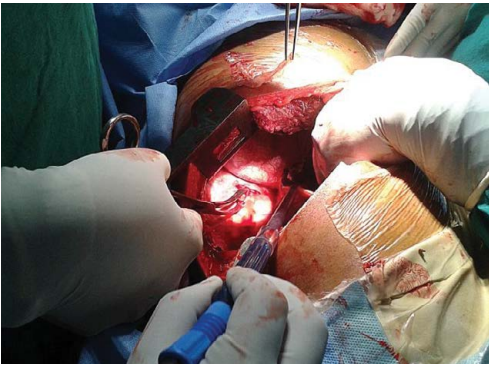


Figure 5 Contusion of lung at the site of lodgement of bullet.

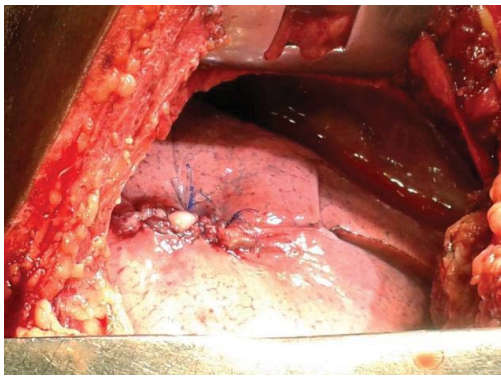


Figure 6 Repaired wound of lung.

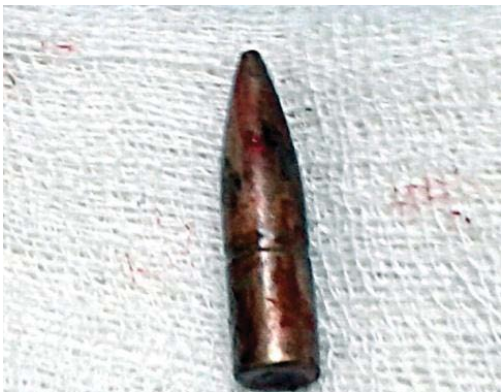

Figure 7 The bullet after removal.

localised with on table fluoroscopy and lateral thoracotomy was done. Bullet was removed and lung contusion repaired. Recovery was uneventful (Figures 6 and 7).

## Discussion

Bullet injury is not uncommon in any part of the world. Presenting complaints as well as presenting time may differ from patient to patient. Injuries to heart or major blood vessels are usually fatal [6]. Cardiac gunshot injuries are usually lethal because of massive haemorrhage or cardiac tamponade [2]. The right ventricle is the commonest site of injury [7,8] as it occupies largest area in anterior chest. Nature and extent of injury depends on the

property of the ballistic, site of injury, speed of the ballistic, presence of pericardial tamponade, injury to associated structure and the condition of the patient during admission [9].

Anesthesia management of thoracic gunshot injury begins with resuscitation in intensive care unit and continue upto postoperative period. ATLS protocol is helpful in these cases. Immediate resuscitation with thoracotomy may be life-saving if there is history of traumatic arrest with prehospital cardiac activity and/or severe hypotension: SBP<70 mmHg [10]. A chest drain should be put at affected side irrespective of presenting symptoms and the drainage may guide further management. Patients with immediate drain output more than 1500ml or continuous bleeding more than 200 ml/hour [10] (as our first case) or continuous air leak (as in our third case) requires immediate thoracotomy. Medical management of gunshot injury must include tetanus prophylaxis, volume resuscitation with blood if blood loss >20% of blood volume, analgesics and antibiotics. Antianxiety medications should be used with caution as these drugs may depress respiration. Antifibrinolytics like tranexamic acid should be used if there is risk of bleeding. The aim of medical management is resuscitation as well as preparation for thoracotomy.

There has been a long controversy regarding recommendations regarding early thoracotomy in gunshot injury. Geramy et al. [11] in 1968 examined 103 patients admitted with penetrating thoracic injury in 7 years period and opined in favour of reserving thoracotomy for those not responding to conservative measures. In 2014, Kong et al. [12] recommended the same for penetrating chest injury with pleural collection. But Tan BK, et al. [13] found better survival with emergency thoracotomy in these patients. Importance of early thoracotomy has been further emphasized by Huth and Hoffmeister [14] who have clearly indicated several advantages. The authors' opinion goes in favour of early and aggressive management. In the face of possibility of embolisation or migration of the bullet or pellets or infection or fibrosis arising from offensive material within the thoracic cavity, it is always better to explore the wound before complication occurs.

Perioperative anesthesia management also may differ from case to case. We considered rapid sequence induction as this was emergency surgery and fasting status was unconfirmed. We used double lumen Endobronchial tube (DLT) for ventilation as it aids independent ventilation of the unaffected lung, protects the unaffected lung from blood and other obnoxious material of the affected lung and provides better view for surgery. We introduced the DLT with an introducer stellate and confirmed its position with alternate clamping and auscultation. Postoperative analgesia was provided with intravenous paracetamol and bupivacaine via thoracic epidural route (multimodal analgesia). Thoracic epidural catheter was introduced after completion of surgery. As hemostasis had been already achieved and volume status was restored, there was little risk of severe hypotension.

## Conclusion

Successful management of thoracic gunshot injury depends on identification of danger signs, proper resuscitative measures, timely intervention and not to deny thoracotomy

when it is required. Immediate intercostal tube placement, volume restoration with blood transfusion when necessary, antifibrinolytics, antibiotics, analgesics forms the mainstay of

management. Double lumen tube and epidural analgesia is safe and effective practice.

## References

- 1 Velinović M, Vranes M, Obrenović-Kirćanski B, Putnik S, Mikić A, et al. (2012) Penetrating wound of the heart manifested with peripheral embolism--case report. *Vojnosanit Pregl* 69: 803-805.
- 2 Buckman RF Jr, Badellino MM, Mauro LH, Asensio JA, Caputo C, et al. (1993) Penetrating cardiac wounds: prospective study of factors influencing initial resuscitation. *J Trauma* 34: 717-725.
- 3 Asensio JA, Berne JD, Demetriades D, Chan L, Murray J, et al. (1998) One hundred five penetrating cardiac injuries: a 2-year prospective evaluation. *J Trauma* 44: 1073-1082.
- 4 Degiannis E, Loogna P, Doll D, Bonanno F, Bowley DM, et al. (2006) Penetrating cardiac injuries: recent experience in South Africa. *World J Surg* 30: 1258-1264.
- 5 Campbell NC, Thomson SR, Muckart DJ, Meumann CM, Van Middelkoop I, et al. (1997) Review of 1198 cases of penetrating cardiac trauma. *Br J Surg* 84: 1737-1740.
- 6 Velinovic M, Velimirovic D, Vranes M, Djukic P, Mikic A, et al. (2009) Heart injuries – still a challenge for cardiac surgery. *The Open Cardiovasc Thorac Surg J* 2: 38-42.
- 7 Symbas PN, Harlaftis N, Waldo WJ (1976) Penetrating cardiac wounds: A comparison of different therapeutic methods. *Ann Surg* 183: 377-381.
- 8 Harrahill M (2002) A patient with transmediastinal gunshot wound. *J Emerg Nurs* 28: 596-598.
- 9 Bali HK, Vijayvergiya R, Banarjee S, Kumar N (2003) Gunshot injury of the heart: an unusual cause of acute myocardial infarction. *Tex Heart Inst J* 30: 158-160.
- 10 Trauma Org guidelines.
- 11 Gerami S, Cousar JE, Davis JM, Moseley TM (1968) The Management of Gunshot Wounds of the Chest. *Ann Thorac Surg* 5: 189-192.
- 12 Kong VY, Sartorius B, Clarke DL (2014) The selective conservative management of penetrating thoracic trauma is still appropriate in the current era. *Injury*.
- 13 Tan BK, Pothiwala S, Ong ME (2013) Emergency thoracotomy: a review of its role in severe chest trauma. *Minerva Chir* 68: 241-250.
- 14 Huth C, Hoffmeister HE (1987) [Penetrating chest injuries--an indication for early thoracotomy]. *Zentralbl Chir* 112: 1011-1022.