

## A Case Report of Acalculus Gall Bladder Perforation with Huge Abdominal Cyst

Ahmed Siddique Ammar\*,  
Zahra Sattar, and  
Syed Asghar Naqi

### Abstract

**Background:** Gallbladder perforation present in various forms with most common is the peritonitis. Most common causes include gallstones obstructing the cystic duct and necrosis of gall bladder due to ischemia.

**Case presentation:** A 19-year-old female presented in the emergency department of EAST Surgical Ward of MAYO Hospital Lahore, Pakistan with history of abdominal distension for 4 months for which she was counseled to be because of pregnancy. She gave birth to healthy baby one month back but abdominal distension didn't resolve. On examination, she had distended and tender abdomen with visible striae. She was tachycardiac with pulse of 124 per minute and blood pressure of 110/80 mmHg. Fluid cytology showed negative for malignant cells and total leukocyte count of  $17 \times 10^9/l$ . Abdominal ultrasound showed a huge thick-walled cystic area with internal echoes measuring 31 cm  $\times$  19 cm  $\times$  19 cm with total amount of fluid volume in the cyst was approximately 5 liters arising from right hypochondrium. On opening the abdomen, a huge cyst was encountered extending from epigastrium to pelvis with dense adhesions. Cyst was opened and fluid aspirated. Communication between cysts was found with gall bladder inn the epigastrium. Cyst wall was excised partially and cholecystectomy done. Patient was discharged on 5th post-operative day.

**Conclusion:** The development of thick-walled huge cyst within abdominal cavity after gall bladder perforation is a rare entity especially when patient had gone through full term pregnancy in the presence of cystt.

**Keywords:** Gall bladder; Perforation; Cyst; Pregnancy; Fistula

Surgical Unit-I (EAST Surgical Ward), MAYO Hospital, Lahore, Pakistan.

**\*Corresponding author:**

Ahmed Siddique Ammar

✉ [asammar1912@gmail.com](mailto:asammar1912@gmail.com)

Surgical Unit-I (EAST Surgical Ward), MAYO Hospital, Lahore, Pakistan

Tel: 0333998191

**Citation:** Ammar AS, Sattar Z, Naqi SA (2020) A Case Report of Acalculus Gall Bladder Perforation with Huge Abdominal Cyst. J Univer Surg. Vol.8 No.6:2

**Received:** November 16, 2020; **Accepted:** December 07, 2020; **Published:** December 14, 2020

### Introduction

Gallbladder perforation is a rare presentation encountered in the surgical emergency floor [1]. The most common mode of presentation of gall bladder perforation is peritonitis but the pre-operative diagnosis of gall bladder perforation is difficult to make especially where there is no availability of advance imaging techniques like CT scan [2]. This delay can result in morbidity and even mortality of the patient with significant influence on the outcomes. The reported incidence of gallbladder perforation in patients with acute cholecystitis is 2–18% while the incidence of gallbladder perforation because of acalculous cholecystitis is about 10 to 20%. The exact mechanism of gall bladder perforation in patients with acalculous cholecystitis is not understood [3]. In some

patients of acalculous cholecystitis the impacted stone in the cystic duct fall back into gallbladder and this resolves the cholecystitis while if this inflammation don't get resolved then persistent inflammation causes the development of empyema which inurn leads to necrosis and eventually perforation [4]. In most of the cases where perforation occurs at fundus, omentum is least likely to cover the perforation so gross peritonitis occurs. On the other hand, if perforation occurs at neck or the duct it is most commonly get sealed by omentum or the intestines which results in either local inflammation. The duration of symptoms may extend from one week to several months [5].

In this case report, we present a case report of 19-year female presented to surgical emergency department with sign and symptoms of huge intra-abdominal cyst. The patient had history

of spontaneous vaginal delivery of a full-term healthy child one month back. On exploration this huge intra-abdominal cyst was communication with the fundus of the gall bladder and no stones were found in gallbladder or the cyst.

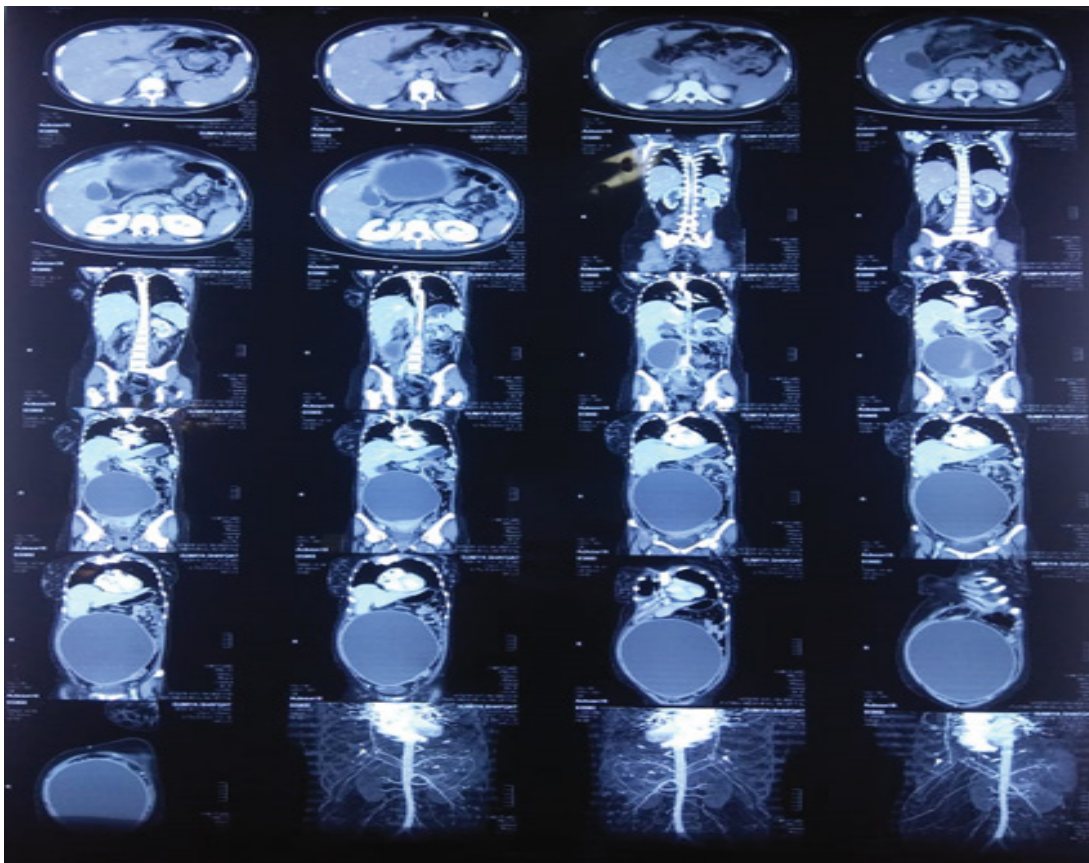
## Case Presentation

A 19-year-old female presented to the emergency department of EAST Surgical ward of MAYO Hospital Lahore, Pakistan in September 2020 with chief complaint of abdominal distension and off and on vomiting and fever for 4 months. She was married one year back and one month back she gave birth to a healthy baby through spontaneous vaginal delivery. On detailed history taking, she told that, she had experienced excruciating pain in right hypochondrium 4 months back for which she was counselled to be because of pregnancy and pain killers were given at a local village hospital. She took symptomatic treatment for off and on pain, vomiting and fever and gave birth to a baby one month back. After giving birth to the baby the abdominal distension remained the same with fever and vomiting for which she now presented to MAYO Hospital.

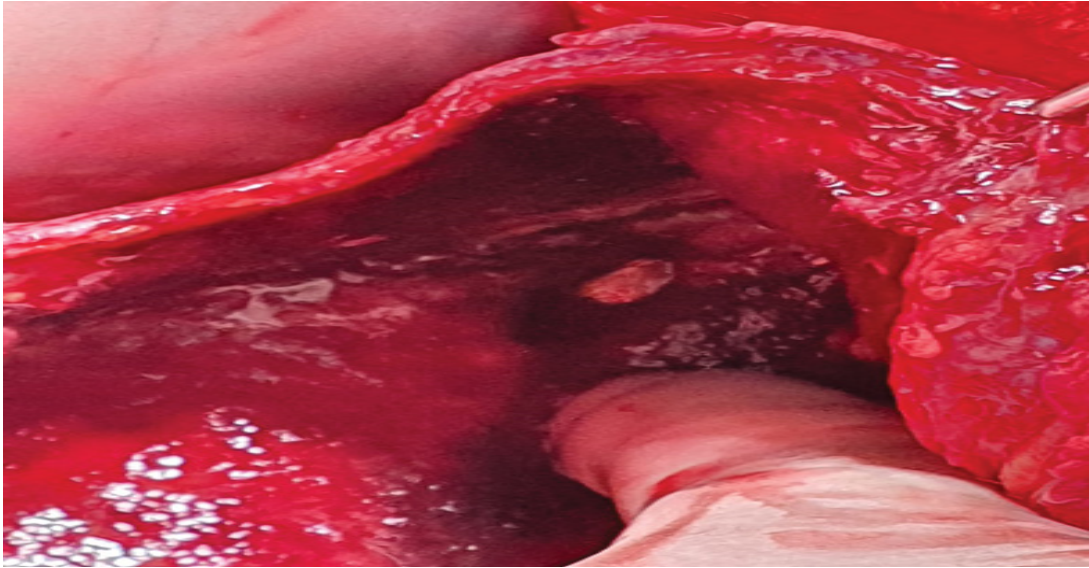
On examination, she had distended and tender abdomen with visible striae. She was tachycardiac with pulse of 124 per minute and blood pressure of 110/80 mmHg, normal respiratory rate, fever of 100-degree Fahrenheit and Glasgow Coma Scale of 15/15. She already had blood tests including complete blood count, liver

function tests and renal function tests which were all in normal range and cytology of the fluid aspirated from the abdominal cyst from another hospital. Fluid cytology showed negative for malignant cells, neutrophils 95%, lymphocytes 5%, total leukocyte count of  $17 \times 10^9/l$ . Chest x-ray and abdominal X-ray erect was done which showed normal lung fields and diffusely increased density of the abdomen, poor definition of the soft tissue shadows, such as the psoas muscles, liver and spleen. Abdominal ultrasound showed a huge thick-walled cystic area with internal echoes measuring 31 cm  $\times$  19 cm  $\times$  19 cm with total amount of fluid volume in the cyst was approximately 5 liters arising from right hypochondrium. Because of the advantage of availability of CT Scan in the emergency department, CT Scan was done and it showed same findings as abdominal ultrasound with finding of superior part of the collection with the fundus of gall bladder, possibly secondary to the perforation of the gallbladder and causing mass effect on small intestines, urinary bladder and ureters (**Figure 1**). After resuscitation and giving broad spectrum antibiotics, plan of exploratory laparotomy was made after taking informed and written consent from the patient for exploration under general anesthesia and after arranging 2 pints of blood.

On opening the abdomen, the cyst wall is encountered just after cutting the peritoneum with layer of omentum overlying the cyst wall. The peritoneum was adherent to the cyst wall. After separating the peritoneum from cyst on both lateral sides, all of small intestine



**Figure 1** CT scan of the patient showing huge abdominal cyst



**Figure 2** Inside view of the cyst after opening showing thickness of the cyst wall and communication with the gall bladder fundus.

**Table 1** Summary of the case.

|                              |  |
|------------------------------|--|
| <b>Patient (Gender, Age)</b> | A 19-year old female   |
| <b>Final Diagnosis</b>       | Gall bladder perforation                                     |
| <b>Symptoms</b>              | Abdominal distension and vomiting                            |
| <b>Medications</b>           | Gram positive and third generation cephalosporins.           |
| <b>Clinical Procedure</b>    | Exploratory laparotomy, excision of cyst and cholecystectomy |
| <b>Specialty</b>             | General surgery/gastroenterology.                            |

was found in left flank and large intestine on the right flank with dense adhesions. Cyst was occupying the whole abdomen from epigastrium to pelvis on both flanks. Lower limit of the cyst was identified and cyst was opened by creating a small opening in the anterior wall of the cyst and about 6 liters of purulent fluid was sucked through the cyst. Cyst was then opened up to epigastrium where a small opening was observed which was communicating to the fundus of the gallbladder (**Figure 2**). The posterior surface of cyst was densely adherent to the aorta, major vessels and uterus and the posterolateral surface was adhered to colon so the wall of the cyst was excised up to the adhesions and rest of the cyst wall was left behind because of chances of iatrogenic injury to major vessels. In right hypochondrium gall bladder was identified with communication with the cyst and cholecystectomy was done. Single drain was placed in pelvis. Surgery and postoperative period remained uneventful and patient was discharged on 5th post-operative day (**Table 1**).

## Discussion

Courvoisier first described 499 cases of gallbladder perforation in 1890 out of which 169 developed cholecysto-cutaneous fistulae. However, in past 50 years, less than 25 cases have been reported in the literature and this decline is mostly due to the inventions in advanced imaging techniques, surgical treatments and antibiotics [6]. Niemeier in 1934 classified gall bladder perforation into three types. Type 1 includes patients with free perforation into the peritoneum. Type II includes patients with localized perforation and

type III includes patients with chole-cysto-biliary fistula and complex fistula formation [7].

Spontaneous gallbladder perforation or rupture is a well-documented complication of acute cholecystitis. The morbidity and mortality due to gallbladder perforation is estimated to be 57.7% and 9.5% respectively [8]. The most common age group affected by gall bladder perforation is between 48 to 60 years. Free perforation of the gallbladder is rare and the most common site of gallbladder perforation is fundus. Many case reports about gallbladder perforation are available in literature but still many controversies exist regarding the best tool for early diagnosis and the treatment modality [9]. Ultrasound abdomen is still the main investigation of choice in emergency and elective procedures but it can't tell details about the perforation. For that CT Scan is the most sensitive tool to diagnose gallbladder perforation [10].

Perforation of the gallbladder can develop early in the course of acute cholecystitis or it may occur several weeks after the onset. Because of the poor blood supply fundus is the most common site of perforation [11]. Localized perforations can be found in literature but such a huge cyst with communication with the gall bladder is first of its kind [12].

This case is first of its kind and much different from the literature of gallbladder perforation available as in this case there is a history of about 4 months from the start of the symptoms and surprisingly no gross peritonitis occurred. Instead a well-formed thick wall was

formed which was communicating with the gall bladder fundus. The secretions of the gall bladder were poured in the cyst for the last 4 months increasing the size of the cyst with the passage of time. The most interesting thing is that the patient got pregnant and delivered a healthy baby in between this condition.

## Conclusion

Localized collection of the gall bladder perforation is reported in literature but a localized collection with well-developed thick wall extending up to the pelvis is first of its kind. Moreover, in the presence of such huge cyst patient also underwent pregnancy and delivered a healthy full-term baby. There were no sign and symptoms of peritonitis in 4 months of history. This case showed an

unusual presentation of gall bladder perforation and this case adds case report in the literature.

## Consent for Publication

A written consent was taken from the patient.

## Ethical Approval

Ethical approval is not required at our institution to publish an anonymous case report.

## Funding

This article does not receive any funding.

## References

- 1 Date RS, Thrumurthy SG, Whiteside S, Umer MA, Pursnani KG, et al. (2012) Gallbladder perforation: A case series and systematic review. *Int J Surg* 10: 63-68.
- 2 Badru F, Litton T, Puckett Y, Bansal S, Guzman M, et al. (2016) Spontaneous gallbladder perforation in a child secondary to a gallbladder cyst: a rare presentation and review of literature. *Pediatr Surg Int* 32: 629-634.
- 3 Goel V, Kumar N, Soni N (2015) Ruptured gall bladder containing stones following blunt trauma abdomen: a rare presentation of hemodynamic instability. *J Nepal Med Assoc* 53.
- 4 Hussain T, Adams M, Ahmed M, Arshad N, Solkar M (2016) Intrahepatic perforation of the gallbladder causing liver abscesses: case studies and literature review of a rare complication. *Ann R Coll Surg Engl* 98: e88-e91.
- 5 Imtiaz H, Somasundaram M, Dutton J, Hariharan D, Yip V, et al. (2020) Extrahepatic bile duct neuroendocrine tumour: A rare presentation in an 18-year-old female. *HPB* 22: S188-S189.
- 6 Khan MR, Begum S (2020) Isolated gallbladder injury from blunt abdominal trauma: A rare co-incidence. *J Pak Med Assoc* 70: S95-S98.
- 7 Malik MN, Mahmood T, Din AT, Aslam S, Imtiaz M (2019) Gallbladder Perforation Secondary to Enteric Fever: An Interesting Case of Acute Abdomen. *Cureus* p. 11.
- 8 Mughal Z, Green J, Whatling PJ, Patel R, Holme TC (2017) Perfoation of the gallbladder: 'Bait' for the unsuspecting laparoscopic surgeon. *Ann R Coll Surg Engl* 99: e15-e18.
- 9 Natarajan M (2017) Gallbladder perforation, though a rare presentation of acute abdomen needs immediate intervention and utmost expertise in its management. *Univ J Surg Surgical Specs* 3.
- 10 Pun B, Karki B, Shrestha B, Pathak R, Shrestha PS, et al. (2020) Diagnostic utility of ultrasonography and computerized tomography in gall bladder perforation: A case report. *Radiol Case Rep* 15: 1905-1908.
- 11 Ramesh A, Balakrishnan R (2017) Gallbladder perforation-presenting as an acute abdomen. *J Evol Med Dent Sci* 6: 5647-5652.
- 12 Sen S, Parui UK (2018) Spontaneous Gall Bladder Perforation: A rare clinical entity, a diagnostic and surgical challenge. *Surg Med Open Acc J* 1: 1-4.